

Repetitive transorbital alternating current stimulation in optic neuropathy

Carolin Gall^a, Anton B. Fedorov^b, Lisa Ernst^a, Antonia Borrmann^a and Bernhard A. Sabel^a

^a*Otto-von-Guericke University of Magdeburg, Medical Faculty, Institute of Medical Psychology, Magdeburg, Germany*

^b*EBS Technologies GmbH, Kleinmachnow, Germany*

Abstract. *Background:* Visual field defects after optic nerve damage typically show a limited capacity for spontaneous and treatment-induced recovery.

Objective: Repetitive transorbital alternating current stimulation (rtACS) was applied to the damaged optic nerve to evaluate visual functions after stimulation.

Methods: A 27-years-old male patient suffering left optic nerve atrophy with nearly complete loss of vision 11 years after atypical traumatic damage was treated transorbitally with biphasic 10–15 pulse trains of rtACS (10–30 Hz, < 600 μ A, 30–40 min daily for 10 days) which produced phosphenes.

Results: After rtACS treatment detection ability of super-threshold stimuli increased from 3.44% to 17.75% and mean perimetric threshold from 0 dB to 2.21 dB at final diagnostics.

Conclusion: This improvement of vision may be due to increased neuronal synchronization, possibly involving strengthening of synaptic transmission along the central visual pathway.

Keywords: Alternating current, electric stimulation, traumatic optic neuropathy, vision recovery

1. Introduction

Vision loss after traumatic optic neuropathy is often severe [20]. However, spontaneous improvements of visual acuity in untreated patients after optic nerve trauma occurs in about 50% of cases at three months post lesion [7]. Because so far all therapeutic interventions including corticosteroid therapy or optic canal decompression surgery were not found to be effective enough [7,23,24], there is a need to evaluate new treatment procedures for persistent vision loss.

Animal studies have shown that electrical stimulation promotes the survival of retinal ganglion cells in rats after axotomy of the optic nerve [12]. Transcorneal electrical stimulation in humans was already used to

stimulate retinal ganglion cells and their axons [9,16]. In a clinical setting a Japanese group found that electrical stimulation may be able to improve visual functions in patients with optic nerve damage [5]. They applied transcorneal electrical stimulation (bursts of 20 biphasic pulses, duration 10 ms, 20 Hz, 30 min) with a contact lens-type stimulating electrode. Increased visual acuity was observed in 2 of 3 treated eyes with nonarteritic ischemic optic neuropathy and in 4 of 5 treated eyes with traumatic optic neuropathy after only one session of electrical stimulation [5]. In this study the threshold current necessary to elicit phosphenes was assessed by increasing current from 300 μ A to 2 mA at a frequency of 10 Hz [5]. Observed threshold currents in neuropathy patients were between 600 and 800 μ A [5]. Transcorneal electrical stimulation was also used to assess the threshold current to evoke phosphenes in patients with retinitis pigmentosa as a measure of residual function of surviving retinal ganglion cells with thresh-

Address for correspondence: Carolin Gall, Institute of Medical Psychology, Leipziger Str. 44, 39120 Magdeburg, Germany. Tel.: +49 391 672 1807; Fax: +49 391 672 1803; E-mail: Carolin.Gall@med.ovgu.de.

old currents in patients well above normal levels [10, 11,17].

To further explore the vision restoration potential of non-invasive electrical stimulation we measured the threshold current to evoke phosphenes applying different pulse shapes in a patient with monocular traumatic optic neuropathy who was treated on ten consecutive days. Effective parameters for optimal bright phosphene elicitation were recorded daily. RtACS elicited phosphenes even when stimulating the damaged eye and additionally resulted in significant improvements in visual functions.

2. Methods

2.1. Case history

A 27-year-old male patient presenting with optic nerve lesion at the age of 16 was evaluated in an exploratory study from Oct 2007 to March 2009. The patient gave informed written consent to participate in the study which was carried out in accordance with the Declaration of Helsinki and ethical committee approval.

The nearly complete visual field loss of the left eye was caused by optic nerve damage after accidental eyeball perforation with a screw driver while working as a motor mechanic. There were no signs of progression or recovery of the visual field in the year prior to our study as revealed by standard perimetry results provided by the patient's ophthalmologist. Perimetric visual field examinations of the left eye documented a complete loss of vision in static near-threshold perimetry (Twinfield, Oculus, Lynnwood, WA). However, monocular computer campimetry with super-threshold light stimuli revealed 3.44% residual light perception in the lower temporal quadrant of the left eye at baseline. In the same quadrant moving targets presented with maximum brightness could be detected during the kinetic visual field evaluation.

Further, the patient reported photosensitivity and intermittent diplopia in the lower-temporal quadrant of the visual field of the affected left eye.

The eye ball perforation caused optic nerve damage with a paresis of the left oculomotor and abducens nerve. Secondary exotropia was observed that was reduced by strabismus surgery in 1998 because residual visual perception in the left lower temporal quadrant was supposed to be strong enough to result in an intermittent diplopia when the visual axis of the left eye diverged. Because of the loss of parasympathetic innervation the patient showed mydriasis with photosensitivity.

2.2. Diagnostic evaluation of the visual field

The ophthalmologic examination included tests of visual acuity, static perimetry (Twinfield Oculus, 66 positions, 30° visual field, targets III/4 mm², colour: white, luminance: 318 cd/m²/ 0 db, duration: 0.2 s presented on a background with a constant luminance of 10 cd/m²), kinetic perimetry (Twinfield Oculus, 0 dB, 24 meridians, velocity 2°/s), and a static computer campimetric visual field test [13]. These tests were applied the day before and the day after the 10-day-treatment-course of rtACS and again at 2-months and 1.5-years follow-up. Monocular full-field checkerboard visual evoked potentials (VEP) measurements (Neuromian, Medicom Mtd, Taganrog, RU) were conducted pre and post rtACS for the lesioned eye only.

2.3. Visual acuity and object perception

Visual acuity was measured monocularly using a Snellen test chart which was presented at a distance of 6 m for distance vision and the Landoldt-ring test at a distance of 40 cm for near vision.

The visual object and space perception battery (VOSP) was assessed before and after rtACS [21]. This is a neuropsychological tool consisting of 7 different tests to detect impairments of cognitive function in patients with partial brain damage allowing comparison with statistical standard values of healthy controls. Five of 7 tests were chosen to analyze the ability to detect shapes of incomplete letters, the total number of presented dots, the relative position of dots in a square and the configuration of numbers in a square.

2.4. Repetitive transorbital alternating current stimulation (rtACS)

Alternating current bursts were delivered with a non-invasive brain stimulation device (EBS Technologies, Kleinmachnow, Germany). The device was certified for clinical use and the stimulation protocol (see below) was guided by the prior clinical experience obtained in Saint-Petersburg/RU by one of the authors (AF) during the last decade. RtACS was applied extraocularly to both eyes, irrespective of whether the eye was functionally impaired or not in order to achieve maximum stimulation and a subsequent excitability increase in both hemispheres. Four separate stimulating electrodes (sintered Ag/AgCl ring electrode, Easycap, Germany) were attached to the skin of the eyelid or to the region

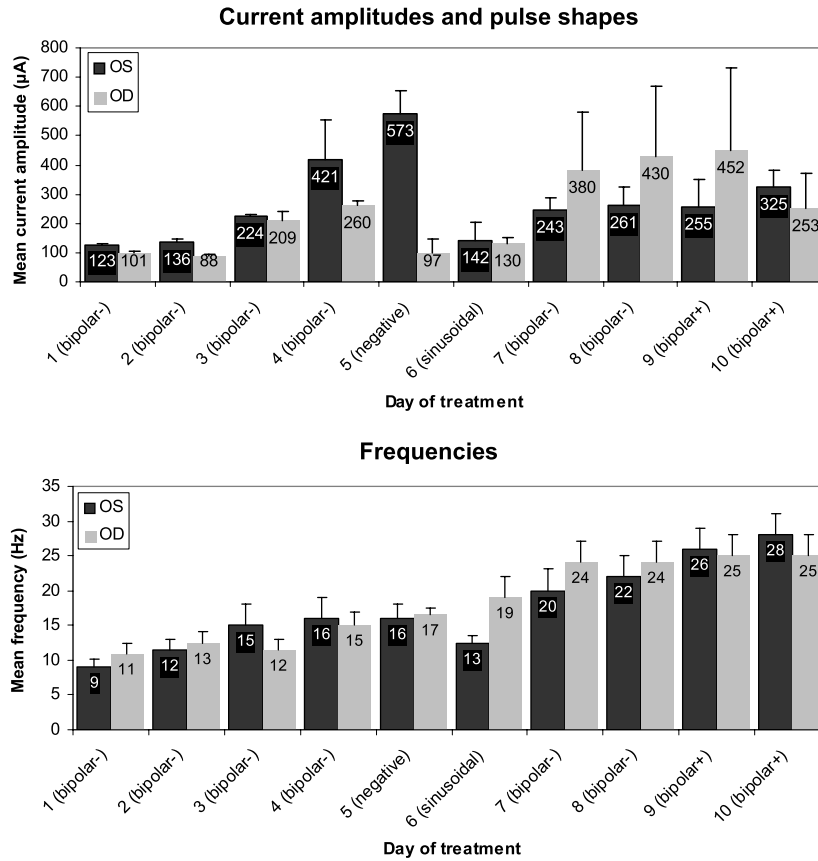


Fig. 1. Stimulation parameters used for the 10 day treatment course (current amplitudes, frequencies and pulse shapes). On 8/10 days biphasic square-wave pulses were applied. On day 4 negative monophasic square-wave pulses and on day 5 sinusoidal biphasic pulses were used.

immediately around the eye while the eyes were closed. The reference electrode was positioned at the forearm.

RtACS was first administered for phosphene elicitation. To this end, bursts of 10–15 pulse trains per channel were applied with a single pulse duration of 8.7 ± 0.8 ms and frequencies ranging from 10 to 30 Hz. Current thresholds were determined every day during the 10-day treatment period for both eyes at a given frequency of 4 Hz. Current thresholds were defined as the value of the electrical current that elicited the first subjectively perceived phosphenes anywhere in the visual field. For this purpose current intensity was increased stepwise (by $10 \mu\text{A}$ per second) starting with $0 \mu\text{A}$. Stimulation frequencies were between the α -range (min) and the flicker fusion frequency (max). Flicker fusion frequency was determined by stepwise increasing the frequency (1 to 5 Hz per second). Throughout the 10-day-treatment course, current and frequencies had to be adjusted to maintain phosphene perception. The amplitude of each current pulse was always below $600 \mu\text{A}$. The length of each

daily session varied between 30 and 40 min depending on the number of stimulation series in each daily session.

3. Results

3.1. Phosphene perception and VEP

Mean current thresholds and frequencies for phosphene elicitation were recorded each day (Fig. 1). The patient perceived phosphenes during stimulation of both eyes, and the average threshold current for phosphene elicitation varied between sessions during the treatment course. Except slight superficial skin irritation no side effect was observed during or after rtACS.

Mean currents required for phosphene elicitation were lowest on the first day and then had to be increased during the stimulation course with constant pulse shape (bipolar), i.e. a habituation (acute plasticity) effect. With a negative rectangular pulse shape

Table 1
Intraindividual results of visual field examinations before and after rtACS and at 2-months and 1.5 years follow-up

Baseline		Post		Follow-up 2-months		Follow-up 1.5 years		Pre vs Post	Pre vs Follow-up 2 months	Pre vs Follow-up 1.5 years
Mean	SD	Mean	SD	Mean	SD	Mean	SD	T(p)	T(p)	T(p)
<i>Static perimetry (Mean threshold in dB), OS (defect eye)</i>										
0.00	0.00	2.21	3.54	3.98	4.73	2.52	4.16	2.75 (< 0.0001)	3.07 (< 0.0001)	4.74 (< 0.0001)
<i>Static perimetry (Mean threshold in dB), OD (intact eye)</i>										
20.39	4.81	21.56	3.03	21.56	3.27	22.15	2.86	4.50 (< 0.0001)	6.18 (< 0.0001)	4.01 (< 0.0001)
<i>Kinetic perimetry (Mean eccentricity of detected stimuli in $^{\circ}$), OS (defect eye)</i>										
31.54	27.77	35.29	24.16	38.13	22.56	40.63	19.85	2.14 (0.043)	2.66 (0.014)	-2.02 (0.056)
<i>Kinetic perimetry (Mean eccentricity of detected stimuli in $^{\circ}$), OD (intact eye)</i>										
60.08	8.65	57.46	10.54	57.75	10.58	59.83	8.95	-3.22 (0.004)	-3.04 (0.006)	3.14 (0.005)
<i>Computer campimetry (relative detection performance in %), OS (defect eye)</i>										
3.44	11.85	17.75	26.88	23.09	29.57	19.22	27.72	12.35 (< 0.0001)	14.68 (< 0.0001)	11.41 (< 0.0001)

on day 5 (the only day without biphasic stimulation) the highest amplitude for phosphenes elicitation was observed; with sinusoidal pulse shape, however, lower currents were sufficient to elicit noticeable phosphenes again. The fusion frequency was 25.4 ± 2.3 Hz in the intact right and 18.5 ± 3.1 Hz in the lesioned left eye.

Comparing full-field checkerboard VEP measurements of the lesioned eye before and after rtACS a N75-P100 complex was observable after the rtACS treatment with a prolonged P100 latency while the pre rtACS measurement presented noise without a detectable complex.

3.2. Visual acuity and object perception

There were no differences of uncorrected visual acuity before vs. after rtACS. Near and far vision scores were about 1.5 for the intact right eye. Far vision could not be measured in the damaged left eye and the near vision value was 1/35.

The maximum score that can be achieved with the VOSP test battery is 80 points in the five selected tests. According to the VOSP-manual a score of less than 65 points indicates a significant object perception deficit. During initial diagnostics the patient showed an almost error-free performance with the healthy right eye (78 points). When testing the impaired left eye object perception deficits were revealed (36 points), these were less severe at final diagnostic (50 points).

3.3. Visual field

Table 1 and Fig. 2 show the results of intraindividual comparisons performed for multiple visual field tests.

For the lesioned left eye significant improvements of the visual field were observed in static (mean threshold improvement of 2.21 dB) and kinetic perimetry (increased eccentricity of visual field border by about 4°) immediately after the rtACS treatment course. In computer campimetry the mean absolute improvement of super-threshold stimuli detection was 14.31% immediately after rtACS with stable improvements at both follow-ups of 19.65% after 2 months and 15.78% after 1.5 years (Table 1). Thus, daily application of rtACS improved stimulus detection performance in the lesioned eye in each of three independent evaluations of the visual field.

However, in the intact eye the mean eccentricity in kinetic perimetry was smaller after rtACS and at follow-up. When presenting the patient with this finding he reported of having made less effort to detect stimuli during the final examination of the intact eye.

After rtACS the patient reported to use both eyes in daily life, however, because of strabismus on the left eye he noticed an increase of diplopia after the course of the treatment.

3.4. National Eye Institute Visual Functioning Questionnaire (NEI VFQ)

The patient's ratings of visual functioning using the self-administered NEI VFQ [8] were compared with a German reference group of healthy male subjects without vision impairments (mean age 30.05 ± 6.27 years, $n = 57$). The patient's ratings revealed substantially diminished scores (subscales general vision, ocular pain,


Computer campimetry and Twinfield Oculus Perimetry in the course of the study

Fig. 2. Detection performance in computer campimetry and static automated perimetry at various times before and after rtACS. Computer campimetry was assessed at four different time points. Depending on the number of correct responses (hits) the visual field position in the chart was defined as seeing (white), blind (black) or as partial (residual) vision (grey). Based on campimetry plots areas of the visual field were characterized as intact, partially damaged or absolutely impaired. Perimetric evaluations of the visual field show areas with physiological adequate light detection thresholds (white), increased thresholds indicating residual vision (grey) and absolutely damaged visual field (black).

mental health, driving, and peripheral vision) compared to the healthy reference group at baseline (Fig. 3), but after rtACS these scores improved and were stable or showed further improvements at the 1.5 years follow-up.

4. Discussion

In a patient with long-term (11-yr old) unilateral post-traumatic optic nerve lesion, increased detection ability was observed in the visual field of the lesioned eye after a 10-day treatment with rtACS.

Similarly, in a Japanese study patients with traumatic optic neuropathy were investigated who reported improvements in visual acuity in 4 of 5 eyes treated with transcorneal electric stimulation [5]. In the present study visual acuity improvements were not observable, however, the patient presented with visual field enlargements after rtACS that were stable for at least 1.5 years. These visual field enlargements were supported by electrophysiological findings, i.e. results of VEP recordings that revealed a previously absent N75-P100 complex after the treatment course. Visual field enlargements were accompanied by the patient's ratings of subjective visual functioning in a standardized questionnaire.

Thus, non-invasive rtACS led to partial recovery of vision even when applied long after the damage occurred. Similar effects were only observed after behavioral training that required many months of daily exercise [6]. We propose that visual field enlargements in patients with visual field defects through rtACS are due to increased neuronal synchronization [4,18]. Our results are compatible with the hypothesis that pulsed, repetitive, non-invasive stimulation induces long-term potentiation-like strengthening of synaptic transmission. Thus some of the lost visual functions are restored by increasing the activity of residual structures [14]. This is in agreement with other studies that used different protocols of direct current stimulation thereby inducing cortical plasticity [1–3,15,19]. Reoccurrence of visual abilities after pre- and postchiasmatic lesions was also reported after after time-consuming behavioral training with repetitive visual stimulation [6,13,22]. Whether transcranial current stimulation enhances the effect of vision restoration therapy is a question for further research.

In summary, rtACS may be a tool to induce partial restoration of vision. A 10-day treatment period was sufficient to induce improvements of vision. A well-controlled clinical trial is now underway to evaluate the efficacy of non-invasive rtACS in a larger patient sample.

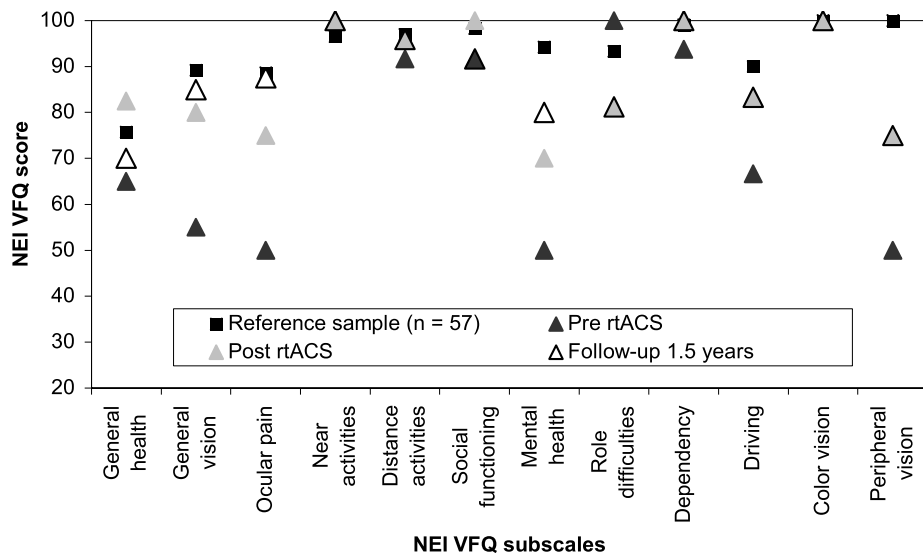


Fig. 3. Subjective ratings of visual functioning. Score range is from 0 (“worst possible functioning”) to 100 (“best possible functioning”).

Acknowledgement

The study was funded by the Otto-von-Guericke University, Magdeburg, Germany. Anton Fedorov is medical director of EBS Technologies GmbH, Germany. Bernhard A. Sabel is founder, consultant and shareholder of the company.

References

- [1] A. Antal, T.Z. Kincses, M.A. Nitsche, O. Bartfai, W. Paulus, Excitability changes induced in the human primary visual cortex by transcranial direct current stimulation: direct electrophysiological evidence, *Investigative Ophthalmology and Visual Science* **45** (2004), 702–707.
- [2] A Antal, M.A. Nitsche and W. Paulus, Transcranial direct current stimulation and the visual cortex, *Brain Research Bulletin* **68** (2006), 459–463.
- [3] L. Chaieb, A. Antal and W. Paulus, Gender-specific modulation of short-term neuroplasticity in the visual cortex induced by transcranial direct current stimulation, *Visual Neuroscience* **25** (2008), 77–81.
- [4] A.B. Fedorov, A.M. Chibisova and J.M. Tchibissova, Impulse modulating therapeutic electrical stimulation (IMTES) increases visual field size in patients with optic nerve lesions, *International Congress Series* **52** (2005), 1282.
- [5] T. Fujikado, T. Morimoto, K. Matsushita, H. Shimojo, Y. Okawa and Y. Tano, Effect of transcorneal electrical stimulation in patients with nonarteritic ischemic optic neuropathy or traumatic optic neuropathy, *Japanese Journal of Ophthalmology* **50** (2006), 266–273.
- [6] E. Kasten, S. Wust, W. Behrens-Baumann and B.A. Sabel, Computer-based training for the treatment of partial blindness, *Nature Medicine* **4** (1998), 1083–1087.
- [7] A.L. Levin, R.W. Beck, M.P. Joseph, S. Seiff and R. Kraker, The International Optic Nerve Trauma Study Group. The treatment of traumatic optic neuropathy, *Ophthalmology* **106** (1999), 1268–1277.
- [8] C.M. Mangione, P.P. Lee, R.R. Gutierrez, K. Spritzer, S. Berry and R.D. Hays, Development of the 25-item National Eye Institute Visual Function Questionnaire, *Archives of Ophthalmology* **119** (2001), 1050–1058.
- [9] Y. Miyake, K. Yanagida, K. Yagasaki, Clinical application of EER (electrically evoked response). (1) Analysis of EER in normal subjects, *Journal of Japanese Ophthalmological society* **84** (1980), 354–360.
- [10] Y. Miyake, K. Yanagida, K. Yagasaki, Clinical application of EER (electrically evoked response). (2) Analysis of EER in patients with dysfunctional rod or cone visual pathway, *Journal of Japanese Ophthalmological society* **84** (1980), 502–509.
- [11] T. Morimoto, T. Tukui, K. Matsushita, Y. Okawa, H. Shimojyo, S. Kusaka et al., Evaluation of residual retinal function by pupillary constrictions and phosphenes using transcorneal electrical stimulation in patients with retinal degeneration, *Graefe’s Archive of Clinical and Experimental Ophthalmology* **244** (2006), 1283–1293.
- [12] T. Morimoto, T. Miyoshi, T. Fujikado, Y. Tano and Y. Fukuda, Electrical stimulation enhances the survival of axotomized retinal ganglion cells in vivo, *Neuroreport* **13** (2002), 227–230.
- [13] I. Mueller, H. Mast and B.A. Sabel, Recovery of visual field defects: a large clinical observational study using vision restoration therapy, *Restorative Neurology and Neuroscience* **25** (2007), 563–572.
- [14] W. Paulus, Outlasting excitability shifts induced by direct current stimulation of the human brain, *Supplement to Clinical Neurophysiology* **57** (2004), 708–714.
- [15] W. Paulus, Transcranial direct current stimulation (tDCS), *Supplement to Clinical Neurophysiology* **56** (2003), 249–254.
- [16] A.M. Potts and J. Inoue, The electrically evoked response of the visual system (EER), *Investigative Ophthalmology and Visual Science* **7** (1968), 269–278.

- [17] A.M. Potts and J. Inoue, The electrically evoked response of the visual system (EER) II. Effect of adaptation and retinitis pigmentosa, *Investigative Ophthalmology and Visual Science* **8** (1969), 605–613.
- [18] B. Sabel, C. Gall, S. Jobke, A.N. Chibisova, J.M. Chibisova and A.B. Fedorov, Restoration of vision with non-invasive electrical brain synchronisation after optic nerve damage, *Abstract for International Conference of Transcranial Stimulation*, Göttingen, 2008.
- [19] G. Schlaug and V. Renga, Transcranial direct current stimulation: a noninvasive tool to facilitate stroke recovery, *Expert Review of Medical Devices* **5** (2008), 759–768.
- [20] J.D. Trobe, *The neurology of vision*, New York: Oxford University Press, 2001.
- [21] E.K. Warrington and M. James, *VOSP – Visual Object and Space Perception Battery*, Pearson Verlag, 1991.
- [22] W. Widdig, B. Pleger, O. Rommel, J.P. Malin and M. Tegenthoff, Repetitive visual stimulation: a neuropsychological approach to the treatment of cortical blindness, *NeuroRehabilitation* **18** (2003), 227–237.
- [23] N. Wu, Z.Q. Yin and Y. Wang, Traumatic optic neuropathy therapy: an update of clinical and experimental studies, *The Journal of International Medical Research* **36** (2008), 883–889.
- [24] P. Yu-Wai-Man and P.G. Griffiths. Steroids for traumatic optic neuropathy, *Cochrane Database of Systematic Reviews* **4** (2007).